



## PATHOLOGY REPORT

**PATIENT: DOE, JOHN**

**ACCESSION NUMBER: T21-22222**

*D.O.B.* 03/15/1982 *AGE:* 39 yrs *SEX:* M

*DATE COLLECTED:* 12/31/2021

*PHYSICIAN:*

*DATE RECEIVED:* 01/01/2022

*ORIGIN* OFFICE

*DATE REPORTED:* 01/04/2022

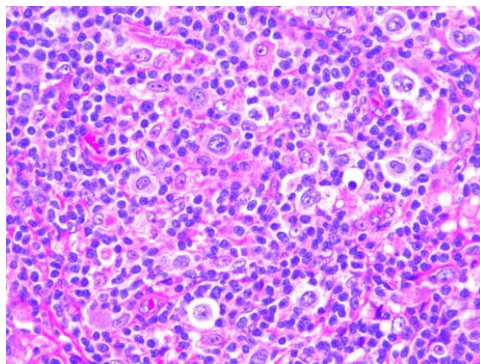
### **Clinical History/Clinical Impression:**

39-year-old male with a history of cervical lymphadenopathy.

### **DIAGNOSIS:**

- A. LEFT CERVICAL LYMPH NODE:  
**MIXED CELLULARITY CLASSIC HODGKIN LYMPHOMA.**

Scattered Hodgkin and Reed-Sternberg cells



### **GROSS DESCRIPTION:**

- A. Labeled with the patient's name and designated LEFT CERVICAL LYMPH NODE, received in formalin are 3 irregular to cylindrical tan-white soft tissue cores and fragments measuring 0.2 to 0.8 cm, which are filtered and submitted in toto in a single cassette.

da

### **MICROSCOPIC DESCRIPTION:**

- A. There is complete effacement of the normal lymph node architecture by an infiltrate of scattered atypical large cells with mono- and bilobed nuclei, irregular nuclear membranes, pale chromatin, and prominent eosinophilic nucleoli (Hodgkin and Reed-Sternberg cells) identified within an inflammatory background consisting predominantly of lymphocytes, plasma cells, with occasional eosinophils.



**Electronically signed by Bryn Haws, DO  
on 01/04/2022 at 12:18pm**